

Revised protocols

Peter Fairbairn and **Minas Leventis** review their practice for true guided bone regeneration.

For true guided bone regeneration we need to help restore the host bone to exactly what it was prior to its damage and loss through disease and resorption process. This healing should be free of the long term presence of slowly or non-resorbing foreign bone graft particles, which may inhibit its ability to turn over, possibly resulting in low quality bone tissue with reduced living osteocyte presence and a sclerotic state.

Thus it is preferable that the ideal particulate bone graft material should be osteoconductive, osteoinductive, biocompatible and totally replaced by host bone over a suitable time. Bone graft substitutes must also be able to maintain volume stability, have good mechanical properties and have no risk for disease transmission. I feel the only material that fulfills these criteria is beta-Tricalcium Phosphate (β -TCP).

New materials such as EthOss (Regenamed, London, UK) have optimised the properties of β -TCP through extensive particle development and by incorporating calcium sulphate, which has enabled the graft to be stable and effectively have its own built in membrane function. Thus with a stable, soft tissue cell occlusive graft a traditional membrane can be dispensed with allowing the host healing to benefit from its own periosteum. I prefer not to use autogenous bone in order to reduce the patient morbidity and possibility of long term volume loss. This element of the bi-phasic material then bioabsorbs first at four to six weeks providing increased porosity for further vascular ingrowth and improved angio-genesis in

the BTcP scaffold.

The same concept has been used successfully for 13 years for a few thousand immediate-delayed implant placements with simultaneous bone grafting. The protocol involves a post-extraction healing period of three weeks to attain a soft tissue coverage, then a site-specific flap is raised retaining the adjacent papillae, the site is thoroughly debrided from all granulation tissue and the implant is placed at the correct 3D position with bone grafting. This immediate-delayed implant placement protocol (simplified regeneration protocol) enables the most effective preservation of host bone by encouraging regeneration prior to the modeling phase.

Case study

The patient, a 68 year old female, presented with a root fracture on a post retained crown of the upper left lateral (fig 1), a common sight in dentistry, with an associated periapical cyst. During extraction the crown fractured off and the retained root tip was removed using a periosteal elevator (fig 2) with the cyst attached to the root. The site was assessed using a probe where it was noted unremarkably the buccal plate was deficient and the socket was allowed to heal with secondary intention.

The upper laterals always have a very thin buccal bone plate and a very buccal root placement at the tooth apex making it an interesting graft case especially long term in this very important aesthetic area. After three weeks soft tissue healing the patient returned for implant surgery showing good closure (fig 3).

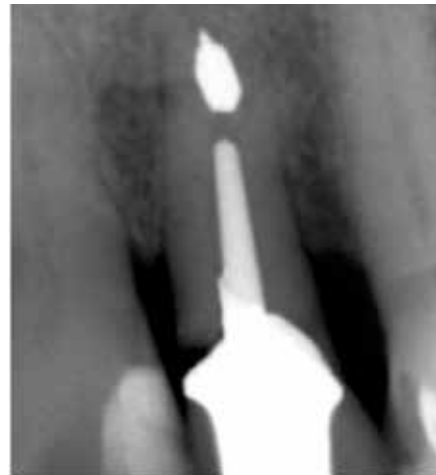

Fig 1. Radiograph of fractured tooth.

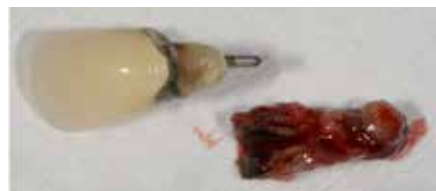

Fig 2. Upper left lateral fractured root.

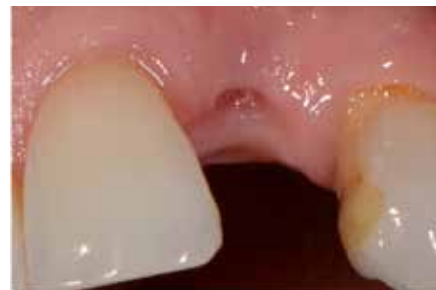

Fig 3. Three weeks soft tissue healing post extraction.

The site specific flap retaining the adjacent papillae was carefully raised to show the buccal bone loss and deficiencies (fig 4). When the flap is raised the vital periosteal blood supply is disturbed and the thin bundle bone will be lost as its periodontal supply was lost at extraction. The site was then extensively curetted to remove any granulation tissue, a very important process to ensure success, and irrigated with sterile saline and chlorhexidine solution.

Once satisfied with the cleansing of the socket the osteotomy was commenced with a sharp pointed initial burr into the palatal wall of the socket. A 2mm pilot drill was then used to attain



Peter Fairbairn

Peter JM Fairbairn is principal at Scarsdale Dental Clinic, Kensington.



Minas Leventis

Minas Leventis is an associate at Scarsdale Dental Clinic, Kensington.

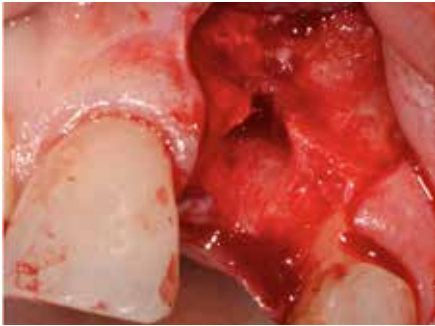


Fig 4. Site specific flap raised retaining papillae.

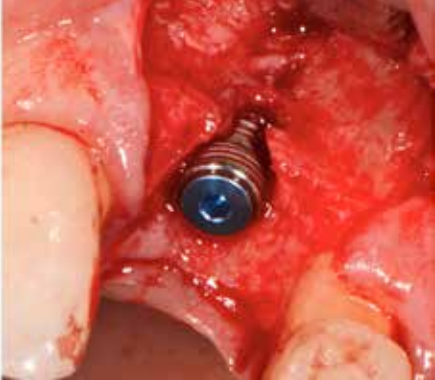


Fig 5. Dio 3,8 by 10 mmm Implant placed showing thin buccal bone with a defect.

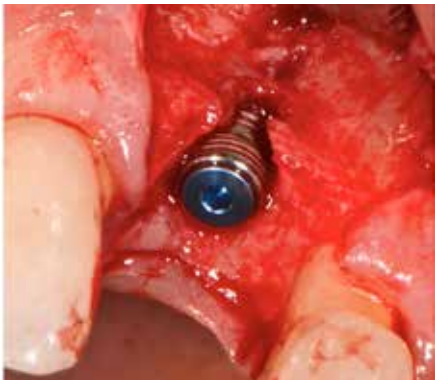

Fig 6. Site Grafted with EthOss and allowed to set.

the correct depth after assessing the angle initially at 6mm with a radiograph. The osteotomy was then finalised with the final drill for the placement of a DIO 3.8 by 10mm SM Implant (fig 5) (DIO Implant Co., Busan, Korea). The early placement of an implant is an important factor in the host regeneration of bone due to its semi-conductive nature and when placed leads to a spike in osteogenesis; there is a further spike with early loading. Due the bone loss the implant only had reduced primary stability as only a few threads were imbedded in host bone and when an Osstell reading was taken using a type 49 SmartPeg, the reading was 44 ISQ.

The site was then grafted with a novel synthetic particulate graft material EthOss (Regenamed, London, UK) which was mixed by adding saline from the dispenser into the syringe material carrier (as per manufacturer instructions); after it

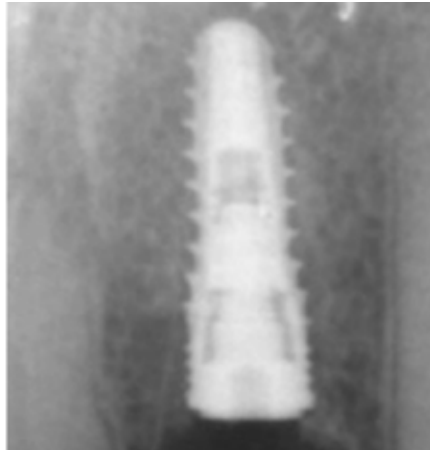


Fig 7. Radiograph of placed Implant and graft.




Fig 8. At 10 weeks showing new bone over the Implant.

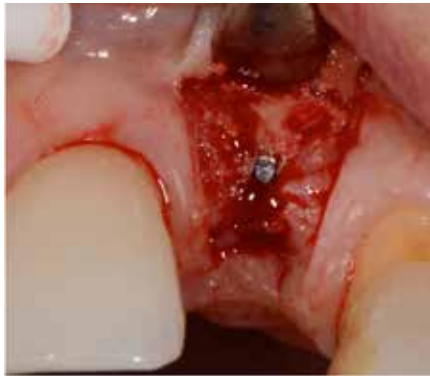

Fig 9. Flap raised at 10 weeks post placement to show new bone regeneration (over implant).

has diffused throughout the material the excess fluid is removed by compressing it onto a sterile gauze. The material is now ready for use and packed in the site using hand instruments. Dry sterile gauze is then again used to compress over the graft to help harden the graft due to its calcium sulphate element thus it is stable and has its own built in membrane (figs 6 and 7). After a five minute setting period the flap is then carefully sutured closed in a tension free manner, this is done using Prolene 4-0 in the aesthetic zone for improved soft

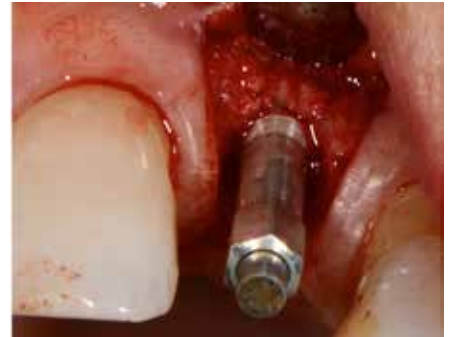

Fig 10. Osstell reading with type 49 peg , of 75 ISQ.

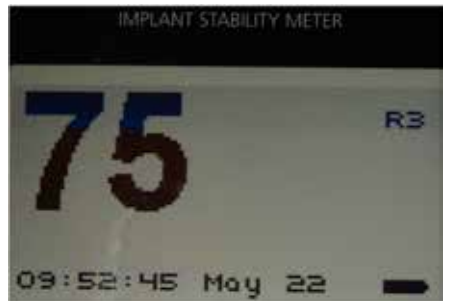

Fig 11. Osstell reading in ISQ.

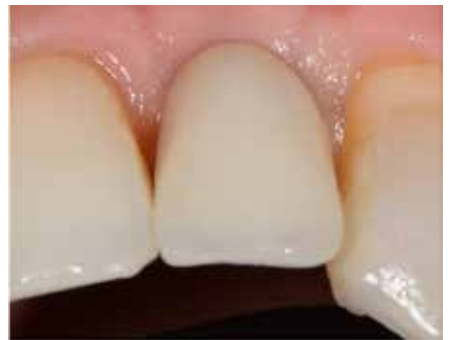

Fig 12. Case loaded 18 Months showing good tissue profile.

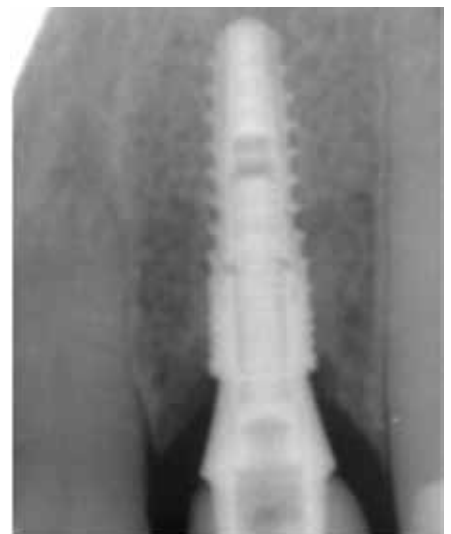

Fig 13. Radiograph of Case Loaded 18 months.

tissue healing, and Coated Vicryl 4-0 (Ethicon, New Jersey, USA) in posterior areas.

The patient was then seen five to seven days later for the removal of the

Sutures where it is routinely noticed that the soft tissue healing is very acceptable due to the bio-compatible nature of the graft material.

After a 10 week healing period the patient returned and a healthy ridge was evident where the profile had been very well retained along with healthy attached gingival tissue. This is an important factor in using graft materials that are fully turned over to host bone as the soft tissue healing is improved. Due to the fact that the new regenerated bone was covering the implant (fig 8), another flap was necessary to access the cover screw. The flap was then carefully lifted showing the new regenerated bone 10 weeks post the placement of the particulate graft (fig 9); as the flap was raised the blood vessels from the periosteum into the new bone could be seen tearing and bleeding indicating the true host bone.

Another Ostell reading was taken and a type 49 peg was then fitted (fig 10) to the abutment after the excess bone covering the implant had been removed using a round burr. The reading now was 75 ISQ (fig 11), so it had gone from 44 to 75 ISQ in a 10 week period – a very good sign of integration and peri-implant bone regeneration. A healing cap was then fitted, the flap sutured closed again

with Prolene 4-0 and the patient advised to use Blue M (Amsterdam, NL) gel on the healing site for improved soft tissue healing.

A week later the sutures were removed and it was noted that the soft tissue healing again was very satisfactory. On removal of the healing cap the gingival depth was assess for the correct abutment selection prior to impressions. The abutment used was a cementable type (SACN 4845 T, Dio Co., Busan, Korea) and was torqued down to 35 Ncm. Impressions were taken using President and a jet bite used to record the occlusion. The crown was then cemented using Premier Implant Cement a further week later ensuring that all excess was removed and the fit checked using a radiograph.

A year later the patient presented for a further follow up appointment. The case was stable and the profile was satisfactory (fig 12). A radiograph (fig 13) backed up the observations showing good regenerated bone levels as by now most, even maybe all, of the material will have been bio-absorbed by host macrophages and osteoclasts being replaced by new host bone. A further benefit of the use of fully bio-absorbed materials is long term assessment can be carried out using routine dental

radiographs as all radio opaque materials placed in the patient will have been turned over to only host opaque tissue .

Conclusion

After over 3,000 grafts over a 13 year period with fully bio-absorbed synthetic particulate graft materials, I feel that the benefits to both patient and dentist alike are clear. The reduced surgical intervention with one procedure using smaller flaps and biocompatible, bacterio-static materials and no autogenous harvesting all leads to dramatically lower patient discomfort and pain.

The returning of the host back to true healthy bone may not only have benefits with the bone to implant interface, but also in the long term stability of the hard and soft tissue with very good profile stability.

The protocol of earlier intervention through grafting and implant placement with materials that appear to up-regulate the host response has allowed us to preserve as well as restore the host tissues.

These materials and protocols appear to be adept at working within the host healing timescale more effectively to help regeneration. The body wants to heal, let's work with it.



3mm of machined surface
R_a 0.9

Rough surface R_a
1.43 with ten years data



the new MSc implant range

machined surface coronally,
with the proven Southern surface
when it's needed most

At Southern Implants, we have been providing innovative solutions to dental professionals since 1987. Solutions like the MSc implant - capturing the advantage of Southern's proven rough surface when it is needed most, to prevent initial failures, and a coronally machined area of specific surface roughness. Indicated for patients with a higher risk of coronal bone loss (smokers, history of periodontitis, cardio-vascular disease).



www.southernimplants.co.uk

Suite 366, Building 3, Chiswick Park, 566 Chiswick High Road, London, W4 5YA, UK | Tel: 0044 20 8899 6846 | info@southernimplants.co.uk