

November 2022

## EFFECTIVENESS OF PLATELET- RICH FIBRIN WITH BETA TRI-CALCIUM PHOSPHATE PLUS CALCIUM SULFATE ON PERIODONTAL INTRABONY DEFECT MANAGEMENT (RANDOMIZED CONTROLLED CLINICAL STUDY)

Nancy Traboulsi

*Resident in Periodontology Masters Program, Faculty of Dentistry, Beirut Arab University, Beirut, Lebanon,*  
nmt174@student.bau.edu.lb

Essam Osman

*Professor of Dental Biomaterials, Faculty of Dentistry, Beirut Arab University, Beirut, Lebanon,*  
essam\_osman@bau.edu.lb

Nayer Abo Elsaad

*Professor of Periodontology, Faculty of Dentistry, Beirut Arab University, Beirut, Lebanon,*  
n.mohamedaboelsaad@bau.edu.lb

Follow this and additional works at: <https://digitalcommons.bau.edu.lb/csdjournal>



Part of the [Oral and Maxillofacial Surgery Commons](#), and the [Periodontics and Periodontology Commons](#)

Intrabony defects, Platelet rich fibrin, Bone graft, Beta tri-calcium phosphate, calcium sulfate

### Recommended Citation

Traboulsi, Nancy; Osman, Essam; and Abo Elsaad, Nayer (2022) "EFFECTIVENESS OF PLATELET- RICH FIBRIN WITH BETA TRI-CALCIUM PHOSPHATE PLUS CALCIUM SULFATE ON PERIODONTAL INTRABONY DEFECT MANAGEMENT (RANDOMIZED CONTROLLED CLINICAL STUDY)," *BAU Journal - Creative Sustainable Development*. Vol. 4: Iss. 1, Article 8.

DOI: <https://doi.org/10.54729/RCMT2642>

This Article is brought to you for free and open access by the BAU Journals at Digital Commons @ BAU. It has been accepted for inclusion in BAU Journal - Creative Sustainable Development by an authorized editor of Digital Commons @ BAU. For more information, please contact [ibtihal@bau.edu.lb](mailto:ibtihal@bau.edu.lb).

---

## EFFECTIVENESS OF PLATELET- RICH FIBRIN WITH BETA TRI-CALCIUM PHOSPHATE PLUS CALCIUM SULFATE ON PERIODONTAL INTRABONY DEFECT MANAGEMENT (RANDOMIZED CONTROLLED CLINICAL STUDY)

### Abstract

The purpose of this study is to evaluate the effectiveness of beta tri-calcium phosphate plus calcium sulfate mix, with or without platelet rich fibrin in reducing probing periodontal pockets clinically and defect depths radiographically, while increasing clinical attachment levels to reconstruct intrabony defects in human clinical trials. Materials and Methods: Sixteen participants with periodontal intrabony defects  $\geq 5$  mm were divided into two equal groups. The first eight intrabony defects in study group received platelet rich fibrin mixed with EthOss®; while the eight remaining intrabony defects in control group were reconstructed only with EthOss® synthetic bone substitute. Freidman ANOVA and Mann-Whitney tests were chosen for intra-group and inter-group comparisons, respectively. Results: Final outcomes revealed statistically significant decrease in periodontal pocket depth and defect depth values ( $P < 0.05$ ) with a statistically significant clinical attachment level gain in study and control groups. Precisely, mean values of all measured categories were greater in study rather than control group participants, as confirmed clinically by William's probe and radiographically by cone-beam computed tomography at 6 months after surgery. Conclusion: Adding PRF to  $\beta$ -TCP plus CS is highly effective in inducing new periodontal soft and hard tissue synthesis resulting in better clinical and radiographic outcomes when surgically incorporated in periodontal intrabony defect(s).

### Keywords

Intrabony defects, Platelet rich fibrin, Bone graft, Beta tri-calcium phosphate, calcium sulfate

## 1. INTRODUCTION

Calcium sulfate CS is an antimicrobial, bacteriostatic and osteoconductive biomaterial that can induce formation of new blood vessels by chemotaxis of platelets at wound site and can differentiate periodontal ligament PDL fibroblasts into osteoblasts and cementoblasts prior to its complete dissolution. Some colleagues incorporated CS to carry antibiotics and growth factors GFs necessary to close postsurgical cystic gaps, conserve alveolar ridges, build three-walled bone defects and fill class II furcations (Mukherji et al., 2016). However, recent studies discussed the effect of CS dissolution on decreasing the pH of grafted area with more GFs and subsequent bone morphogenic proteins' release. This also induced mesenchymal cells to differentiate into bone forming cells and enhanced gene expression to control osteoblastic behavior (Fernandes et al., 2021).

Following periodontal surgery, cells normally populate from adjacent gingival epithelium, gingival connective tissue, alveolar bone and PDL to the healed wound, for new periodontal apparatus formation. Also platelets aggregate at wound site with fibrin formation to initiate release of GFs (Giannobile, 1996).

In previous works, combination of beta tri-calcium phosphate  $\beta$ -TCP with platelet-rich fibrin PRF stabilized blood clots for a long duration, enhanced early bone formation, remodeling and mineralization (Sunitha & Munirathnam, 2008). As to increase quantity of leukocytes, platelets and GFs, the low speed centrifugation concept was introduced to conventional PRF protocol for better tissue regenerative outcomes (Choukron & Ghanaati, 2018). Although few researchers reported positive outcomes in intrabony defects IBDs filled with PRF plus xenograft mix; better clinical and radiographic defect fills were documented using PRF plus allografts (Atchuta et al., 2020).

EthOss® is a bioactive synthetic alloplast composed of 65%  $\beta$ -TCP and 35% CS that can be easily manipulated and adapted to IBD after mixing with saline or patient's own plasma to provide a scaffold for newly formed bone (Leventis et al., 2020). Mukherji et al., in (2016), related absence of inflammation at surgically grafted sites in study and control groups to bacteriostatic potential of fully dissolved CS and resultant lower pH at grafted site. However, Gao et al. in (2016) focused on the role of calcium ions liberated from resorbable CS in providing a pool for bone mineralization.

Previous researchers also combined CS to  $\beta$ -TCP without collagen membrane to enhance the biomechanical properties of  $\beta$ -TCP, speed up new bone maturity, improve wound healing and reduce economic expenses on patients (Sukumar et al., 2010). In 2020, Leventis et al. related success of EthOss® in filling IBD to variations in particle size, porosity and resorption rate of both CS and  $\beta$ -TCP.

Based on the abovementioned literature, this earned our interest to undertake this research. The aim of the study is to evaluate clinically and radiographically the effectiveness of platelet-rich fibrin mixed with beta tri-calcium phosphate plus calcium sulfate, in regeneration of periodontal intrabony defect as regards clinical probing pocket depth and clinical attachment level CAL at 3 and 6 months respectively.

## 2. MATERIALS AND METHODS

### 2.1 Study Design

This randomized controlled clinical trial was carried out after obtaining the validation of Institutional Review Board IRB at Beirut Arab University, IRB approval number: 2020-H-0079-D-M-0418. Suitable candidates were chosen from the Department of Oral Surgical Sciences, Periodontology Specialty Clinics at Beirut Arab University, according to latest periodontitis classification approved by American Academy of Periodontology, precisely stages (II/ III) and grades (A/B) (Tonnetti et al., 2018).

Medical history was recorded and complete blood count was carried out for all patients at baseline to rule out any obstacles that may hinder bone healing in surgical sites. A written informed consent was signed by each patient, following verbal explanation of all treatment procedures.

Phase one therapy was carried out for all patients including coronoplasty if needed. Proper oral hygiene instructions were also advised for (4-6) weeks. Then, probing pocket depth measurements of teeth were rechecked by marked William's periodontal probe. Clinical cases with periodontal pocket depths  $\geq 5$  mm and angular bone loss in patients compliant to planned follow ups at 3 months and 6 months were selected.

Aided by computerized randomization, Randomizer.org was used to allocate sixteen healthy patients, with clinical and radiographical periodontal pocket depth value  $\geq 5$  mm, in two equal groups (n=8) to be treated respectively by EthOss®/PRF mix and EthOss® alloplast.

### 2.1.1 Study group

Eight patients involved with IBD, were subjected to full thickness fully reflected mucoperiosteal flaps, followed by packing (EthOss®/ PRF) mix in such defects. The flap was closed by tension free interrupted sutures.

### 2.1.2 Control group

Eight patients with IBD were subjected to full thickness fully reflected mucoperiosteal flaps to incorporate EthOss® graft at intrabony defective areas. The flap was secured in its place via interrupted sutures.

## 2.2 Inclusion Criteria

- 1) Clinically healthy participants, with no distinction in gender.
- 2) Age range (30-55) years.
- 3) Non-smokers or light smokers (< 5 cigarettes /day).
- 4) Plaque index cases  $\leq 20\%$ .
- 5) Adequate zone of attached gingiva

## 2.3 Exclusion Criteria

- 1) Hypertensive patients.
- 2) Uncontrolled diabetics.
- 3) Immune-compromised patients.
- 4) Pregnant or lactating mothers.
- 5) Patients on anticoagulant therapy or with bleeding disorders.
- 6) Patients with any systemic disease that may affect bone healing.
- 7) Patients with parafunctional habits

## 2.4 Stent Fabrication

For precise standardization of clinical measures, a (2-3) mm thick customized, cold cured acrylic stent was formed after casting registered alginate impressions of arches including IBD. These stents covered the occlusal and the coronal one third of labial/ buccal and lingual/ palatal surfaces of teeth related to intra bony defects in study and in control groups (Singh & Vandana, 2019).

## 2.5 Radiographic Evaluation

At baseline, panoramic x-rays were performed to all suitable candidates. Applying long cone paralleling technique and using Sopix<sup>2</sup> RVG placed in Rinn XCP-DS® FIT™ digital sensor holding device, periapical radiographs of teeth with IBD were executed preoperatively and after 3 months.

Moreover, a digital grid millimeter scale software system in computerized cone-beam computed tomography CBCT of selected quadrants with IBD interpreted the measures between three fixed points at baseline, as presented in Fig. 2(a) & Fig. 3(a) and at 6 months post operatively, as shown in Fig. 2(b) & Fig. 3(b) to execute the amount of newly formed bone along tooth's root surface adjacent to IBD, known as linear bone fill LBF. These fixed points were defect base DB, cement-enamel junction CEJ and bone crest BC. Precisely, DB

is the deepest radiographic bony mark adjacent to healthy PDL space width in IBD involved tooth. CEJ represents the anatomical meeting point between tooth enamel and its root cementum and BC is the most coronal portion of inter proximal alveolar bone contacting tooth's root lateral to IBD (Oh et al., 2019).

## 2.6 Platelet -Rich Fibrin Protocol Preparation

One sample of 10 ml intravenous blood was withdrawn from the superficial vein in the Cubital Fossa into plain glass tubes without any anticoagulant. Within 1 minute, this tube was placed in centrifugation machine (Champion® F-33D) and was balanced by an opposing saline filled glass tube, prior to program running at 3000 RPM /15 minutes at room temperature. At the end of spinning cycle, the collected tubes showed a top plasma liquid layer, a middle gel fibrin rich layer called PRF and a bottom erythrocyte layer (Saluja et al., 2011) as presented in Fig.1.

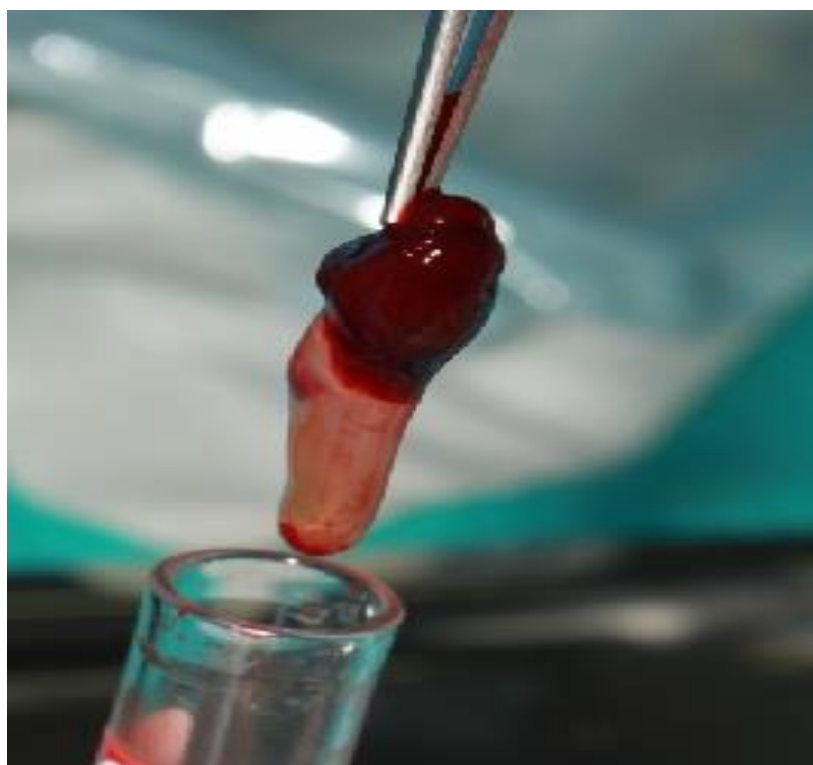


Fig.1: Collection of (PRF) gel from plain glass test tube after blood sample centrifugation.

Reference: Photographed by the author.

## 2.7 Surgical Technique

All surgical procedures were performed under complete aseptic and sterile conditions. At the selected quadrant, an antiseptic septidyne® swab was applied extra-orally and intra-orally. Then, (2%) local anesthetic solution was locally infiltrated. In study and control groups, minimally invasive intrasulcular and interdental papillary preserved incisions around teeth involved and adjacent to IBD were executed with a pen grip, using a 15C blade projected on Bard Parker scalpel handle #3.

By a Molt #9 periosteal elevator, an envelope shaped, full thickness mucoperiosteal flap was bluntly dissected and reflected buccally/ labially (2-3) mm beyond mucogingival junction in addition to full thickness flap reflection of surgical site lingually/ palatally. In both groups, proper removal of the subgingival granulation tissues and thorough root planning were done with After Five® Gracey, site specific curettes. Local saline irrigation was done copiously. Root conditioning using 10% citric acid.

For study group: Superficial plasma in test tubes was aspirated in a 3 ml disposable plastic syringe, to hydrate dry alloplastic bone graft after gentle tapping. At the same time,

the bioactive part of PRF was chopped via #16 Goldman Fox surgical scissors and slowly mixed, within 3 minutes, in sterile PRF bowl with dry EthOss® powder moistened by patient's own plasma. Then, a mix of PRF and EthOss® was carried to surgical area, incrementally, with Lucas curette.

For control group: Depending on the size of bone defect, 0.5 cc or 1 cc of EthOss® bone graft was dispensed in a sterile, stainless steel dappen dish to be mixed with an equal volume of sterile 0.9% saline solution until a flexible paste was obtained and carried to surgical quadrant with Lucas curette to fully pack IBD.

In both groups, gentle application of the prepared bone graft to the intraosseous defect till its bony crest was achieved with an amalgam plugger (3T-Tanner). Final readaptation and closure of mucoperiosteal flap was done with tension free, interrupted, D-tek® sutures, made up of nonresorbable polypropylene threads, size 4/0.

## 2.8 Postsurgical Care

Each patient was advised to quit biting and/ or tooth brushing on the surgically restored quadrant and to take soft food in the first 2 weeks, plus prescribed medications as Amoxil® 500 mg TID for 5 days, Brufen® 400 mg BID for 3 days and Paroex® mouthwash composed of Chlorhexidine Gluconate (0.12%) for 1 minute, BID for 10 days starting from the 3<sup>rd</sup> day after surgery (Sadiq et al., 2020).

## 2.9 Postsurgical Follow up

Within 2 weeks, all interrupted synthetic sutures were removed. Supra gingival scaling was only performed at 3 months and 6 months. Oral hygiene instructions were readvised. Numerical changes in PPD and CAL were recorded at previous calls to the nearest millimeter by a single examiner, using William's periodontal probe in relation to the customized occlusal acrylic stent. Radiologic follow ups were monitored by digital periapical radiography of teeth in IBD via parallel long cone technique at 3 months and CBCT at 6<sup>th</sup> month post-surgery as presented in Fig. 2(b) & Fig. 3(b).

## Statistical Analysis

This randomized clinical trial was executed equally on maxillary and mandibular teeth. All clinical and radiographic parameters were recorded in study and control groups, at baseline, 3 months and 6 months. The mean and standard deviation of collected data of all categories were assessed and compared by Freidman ANOVA and Mann-Whitney tests. Using a computerized IBM® Software, final data analysis was processed by the Statistical Package for Social Sciences SPSS version 24.

Categories with P values less than 0.05 ( $P < 0.05$ ) were considered statistically significant.

## 3. RESULTS

### 3.1 Intra-Group Comparisons: (Freidman ANOVA Test)

#### 3.1.1 Study group

A statistically significant reduction of mean periodontal pocket depth with a  $P$  value = 0.0003 at 3<sup>rd</sup> and 6<sup>th</sup> months following surgery. Mean clinical attachment level values scored statistically significant change at 3<sup>rd</sup> and 6<sup>th</sup> months with a  $P$  value = 0.001. Moreover, mean defect depth amounts were significantly lowered with a  $P$  value = 0.0003 at 3<sup>rd</sup> and 6<sup>th</sup> months as in Table 1.

#### 3.1.2 Control group

Calculated mean of PPD scores recorded at 3<sup>rd</sup> month following periodontal surgery showed a minimal reduction. Yet, at 6<sup>th</sup> month a statistically significant reduction of mean PPD was noted with  $P$  value = 0.003. Minor suppression in mean CAL values was noted at 3<sup>rd</sup> month post surgery. But, a statistically significant decrease in mean CAL scores was recorded at 6<sup>th</sup> month after surgery with a  $P$  value = 0.002. Also, a negligible reduction in mean DD was noted at 3<sup>rd</sup> month compared to a statistically significant reduction in mean DD was clear at 6<sup>th</sup> month with a  $P$  value = 0.00044 as presented in Table 1.

**Table 1: Intra-group comparisons at baseline, 3 months and 6 months (Freidman ANOVA test)**

Category Mean		Baseline (mm)	3 months (mm)	6 months (mm)	P value
Study group	Periodontal pocket depth (PPD)	9.00 ± 0.92	7.00 ± 0.92	5.00 ± 0.75	0.0003*
	Clinical attachment level (CAL)	8.00 ± 0.92	7.00 ± 0.92	5.80 ± 0.99	0.001*
	Depth of the defect (DD)	8.00 ± 0.75	6.75 ± 0.70	5.00 ± 0.53	0.0003*
Control Group	Periodontal pocket depth (PPD)	7.00 ± 0.75	7.00 ± 0.53	6.00 ± 0.53	0.003*
	Clinical attachment level (CAL)	7.00 ± 0.92	6.875±0.83	6.125 ± 0.83	0.002*
	Depth of the defect (DD)	6.12 ± 0.83	6.00 ±0.75	5.00 ± 0.75	0.00044*

\*Denotes statistically significant difference

### 3.2 Inter-group Comparisons: (Mann-Whitney Test)

#### 3.2.1 Differences in mean category measures at baseline and at 3 months:

To determine if there is a statistically significant difference between results obtained from control and study groups at 3 months of surgery, measures of PPD, CAL and DD means obtained at 3 months and at baseline were first subtracted and the resulting differences were executed prior to performing Mann-Whitney test. *P* values less than 0.05 ( $P < 0.05$ ) were statistically significant.

The executed results were related to the following categories:

- 1- Periodontal pocket depth: The calculated outcomes noted U-test = 1 and a statistically significant difference between the variations in mean PPD observed in control and study groups,  $P = 0.001$ . Also, variations in mean rank indicated that values of difference between mean PPD values in case of study group were higher than those in control group as shown in Table 2.
- 2- Clinical Attachment Level: The results obtained marked U-test = 4 plus a statistically significant difference among the variations in mean CAL in control and study groups with  $P$  value = 0.001. Moreover, variations in mean rank emphasized that values of difference between mean CAL values in study group were higher than in control group as clarified in Table 2.
- 3- Depth of Defect: The applied tests on collected data proved a statistically significant difference in mean DD variations observed between control and study groups with  $P$  value = 0.0008. However, variations in mean rank assured that differences within mean DD scores were higher in study group compared to control group as presented in Table 2.

**Table 2: Inter-group category comparisons at baseline and at 3 months (Mann-Whitney U-test)**

			Mann-Whitney U Test		
			Mean Rank	U-test	P value
Difference between measure at baseline and after 3 months	Periodontal pocket depth (PPD)	Control group	4.63	1	0.001*
		Study group	12.38		
	Clinical attachment level (CAL)	Control group	5	4	0.001*
		Study group	12		
	Depth of the defect (DD)	Control group	4.88	3	0.0008*
		Study group	12.13		

\*Denotes statistically significant difference

### 3.2.2 Differences in mean category measures at 3 months and at 6 months:

To determine if there is a significant difference between results in control versus study groups between 3<sup>rd</sup> and 6<sup>th</sup> month post-surgery, mean category values at 6<sup>th</sup> month were subtracted from corresponding values at 3<sup>rd</sup> prior to performing Mann-Whitney U-test for categories as:

- 1- Periodontal pocket depth: Results listed in Table 3 showed U-test = 8 with *P* value = 0.003 that signified a statistically significant difference in mean PPD between variations observed in control and study groups. Whereas, variations in mean rank indicated that values of difference among mean PPD measures in study group were higher than that obtained in control group.
- 2- Clinical attachment level: Related outcomes detected values of U-test = 24 and *P* value = 0.369 which indicated no significant difference in mean CAL variations between control and study groups as shown in Table 3.
- 3- Depth of defect: Scores recorded U-test = 16, while *P* value = 0.0027 that demonstrated a statistically significant difference in mean DD variations among study and control groups. Also, variations in mean rank assured that difference in mean DD values were higher in study group compared to control groups as clarified in Table 3.

**Table 3: Inter-group category comparisons at baseline and at 6 months Mann-Whitney U- test)**

			Mann-Whitney U Test		
			Mean Rank	U-test	P value
Difference between measure after 3 months and after 6 months	Periodontal pocket depth (PPD)	Control group	5.5	8	0.003*
		Study group	11.5		
	Clinical attachment level (CAL)	Control group	7.5	24	0.369
		Study group	9.5		
	Depth of the defect (DD)	Control group	6.5	16	0.027*
		Study group	10.5		

\*Denotes statistically significant difference



### 3.2.3 Differences in mean category measures at baseline and at 6 months:

To determine if there is a significant difference between results in control versus study groups at 6 months after surgery, mean category values at 6<sup>th</sup> month were subtracted from those at baseline prior to performing Mann-Whitney U-test for PPD, CAL and DD categories below:

- 1- Periodontal pocket depth: Results indicated that U-test = 0 with *P* value = 0.0003 affirmed a statistically significant difference between variations in mean PPD observed in study and control groups. Moreover, mean rank values signified that difference between mean PPD in case of study group was higher than those in control group as shown in Table 4.
- 2- Clinical attachment level: Executed outcomes marked U-test = 10 and *P* value = 0.009 confirmed a statistically significant difference between variations in mean CAL observed in control and study groups. While, mean rank scores emphasized that difference between mean CAL in study group were higher than in control group as listed in Table 4.
- 3- Depth of defect: Calculated measures noted U-test = 1.5 and *P* value = 0.001 proved statistically significant difference between variations in mean DD in control and study groups. Moreover, mean rank values assured that the difference between mean DD in study group was higher than in control group as presented in Table 4.

**Table 4: Inter-group category comparisons at baseline and at 6 months (Mann-Whitney U-test)**

			Mann-Whitney U Test		
			Mean Rank	U-test	P value
Difference between measure at baseline and after 6 months	Periodontal pocket depth (PPD)	Control group	4.5	0	0.0003*
		Study group	12.5		
	Clinical attachment level (CAL)	Control group	5.81	10	0.009*
		Study group	11.19		
	Depth of the defect (DD)	Control group	4.69	1.5	0.001*
		Study group	12.31		

\*Denotes significant difference

### 3.2.4 Radiographic bone fill at 6th month after surgery:

Linear bone fill LBF was estimated from the difference of DD measured by CBCT of quadrants involved with IBD between 6 months and baseline. Finally, mean linear bone fill percentage was executed. These values were 37% in study group and 18.39% in control group as shown in Table 5.

**Table 5: Mean linear bone fill percentage at 6 months post surgery**

	Control group	Study group
Mean of percentage of linear bone fill after 6 months	18.39%	37%

1- In Study group:

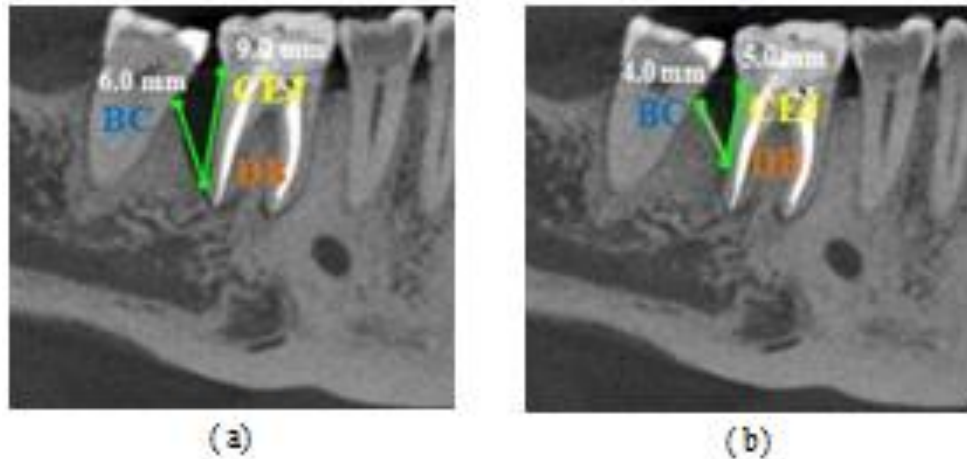


Fig.2: CBCT of lower right quadrant showing first molar with distal defect depth equals to 9.0 mm at baseline (a) and 5.0 mm at 6 months after surgery (b).  
Reference: Photographed by the author.

2- In Control group:

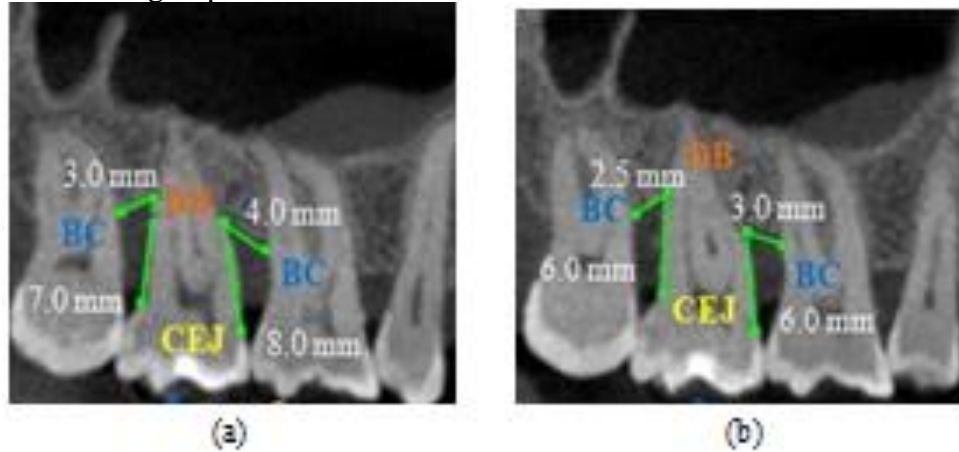


Fig. 3: CBCT of upper right quadrant showing second molar with defect depth measures of 8.0 mm mesially & 7.0 mm distally at baseline (a) and 6.0 mm on mesial & distal root surface at 6th month post surgery (b).  
Reference: Photographed by the author.

#### 4. DISCUSSION

Beta tri-calcium phosphate is an alloplastic synthetic bone graft which is now used extensively for bone defects. It is a bioactive and biocompatible material. It is made up of calcium and phosphorous ions, the main components of bone. It can fully resorb and create many pores to enhance new bone formation and subsequent graft replacement within the defect. Calcium sulfate is an osteoconductive bone graft that resembled cell occlusive membrane rich in calcium ions for bone mineralization.

PRF was preferred over platelet rich plasma PRP due to its cheaper cost, shorter production time and longer duration of liberated GFs without incorporating any synthetic or anticoagulant materials. PRF also provided stem cells and acted as scaffold for tissue cellular attraction to injured site.

The results observed in this randomized clinical trial showed intra-group mean PPD values diminished from baseline by about 2 mm and 4 mm respectively at 3<sup>rd</sup> and 6<sup>th</sup> month intervals in study group. Meanwhile, intra-group mean PPD reduction of about 0.3 mm and 1 mm were recorded in control group at 3 and 6 months after surgery. Thus, mean PPD shrinkage was higher in study versus control groups with an inter-group variation of approximate 1.7 mm at 3 months and about 3 mm at 6 months.

Relatively, gain in mean CAL executed within same group approached 1 mm at 3 months and was doubled to 2 mm in study at 6 months. Yet, gain in mean CAL was 0.1 mm at 3 months compared to about 1 mm surplus in mean CAL at 6 months in control group. Hence, mean CAL gain was higher in study versus control group with approximate relative variation of 0.9 mm at 3 months and 1 mm at 6 months.

In addition, mean DD suppressed by about 1 mm and 3 mm in study group, whereas mean DD reduction scored 0.1 mm and 1.1 mm in control group at 3 and 6 month intervals respectively. So, mean DD reduction was higher in study group rather than in control with an estimate of 0.9 mm and 1.9 mm, respectively at 3<sup>rd</sup> and 6<sup>th</sup> month intervals. However, linear bone fill was greater in study group than in control groups. Precisely, mean linear bone fill's percentage in study group was double than that in control group when calculated at 6 months after surgery.

Similar results were proved in previous studies. As PPD reduction of  $4.55 \text{ mm} \pm 1.87$ , at 6<sup>th</sup> month after PRF sole incorporation in IBD (Sharma & Pradeep, 2011). This is in accordance with another study executed by Pavaniet al. (2021) with a reduction in PPD of  $4.3 \text{ mm} \pm 0.73$  and bone fill range of  $2.51 \text{ mm} \pm 0.97$ , when PRF and  $\beta$ -TCP were utilized in IBD, after 6 months.

Past controversies about reconstructing IBD with sole or combined PRF with biomaterials were proved by some colleagues. Rosama et al. (2012) confirmed stable CAL increase by  $3.36 \text{ mm} \pm 0.38$  with PPD inter-group difference of  $2.29 \text{ mm} \pm 0.3$  in PRF group, 9 months post surgically. Similarly, Bajaj et al. (2013) confirmed a reduction in PPD in PRF study group of  $4.29 \text{ mm} \pm 0.04$  compared to control group  $1.58 \text{ mm} \pm 1.02$ , plus CAL gain of 2.87 mm in study group compared to 1.37 mm in control group, 9 months post operatively. This proved that PRF could induce cellular chemotaxis, strewing and mitosis for rapid wound healing as it could aid in mineralization of newly deposited bone for better quality of regenerated periodontium.

Navageni et al. (2015) related the cause of PPD reduction and CAL gain in PRF group to high amounts of leukocytes present in fibrin clot, subsequent growth factor release, immune regulation, angiogenesis and new bone fill. Similarly, Miron et al. (2017) advised incorporating PRF in IBD due to its unique composition of platelets, leukocytes, cytokines and structural glycoproteins. According to Liu et al. (2019), osteoblastic cell replication before PDL fibroblasts and dental follicle progenitors caused bone fill of IBD by PRF.

Many clinical trials incorporated PRF in periodontal regeneration, with different outcomes. All IBD filled with PRF documented gradual bone synthesis at 6, 9 & 12 months. On radiographs, this fill resembled natural bone (Nagaveni et al., 2015). Galav et al. (2016) confirmed superiority of autogenous bone grafts over PRF in IBD fill at 9 months. In contrast, some colleagues proved stability of new bone in IBD filled with EthOss® for two years post surgery (Leventis et al., 2020).

PRF had limited osteogenic potential, due to its quick resolution. Such drawback necessitated modifications to sole PRF use, by adding bone grafts or drugs to PRF for better quantitative intrabony defect refill as reported by Lei et al. in (2019) and Liu et al. in (2019).

## 5. LIMITATIONS OF THIS STUDY

One of the clinical limitations is variety of produced PRF gel among patients due to tendency of blood to coagulate rapidly in test tubes after 1-2 minutes. Hence, any further delay in handling time may yield to a rapidly degradable fibrin clot and subsequent poor tissue healing. The other limitation is undesirable centrifugation machine vibrations that may cause alteration in PRF's 3D structure, cellular to fibrin ratio and release of GFs. This requires standardization of PRF quantity for best clinical and radiographic outcomes. In addition, enrolling a limited number of 16 participants, within a 6-months observation period, makes evaluating collected data futile.

In the light of these facts, further long-term clinical trials with bigger sample size are recommended to measure further improvements in clinical and radiographical parameters for 12 months duration and to check stability of newly formed periodontium.

## 6. CONCLUSIONS

Introducing PRF is safe and effective in empowering the osteogenic potential of  $\beta$ -TCP plus CS. Moreover, absence of any undesirable antigenic reaction to hard or soft tissues confirmed patient's comfort and clinical safety of this alloplastic/ PRF mix. Hence, incorporating PRF to a composite bone grafts in IBD  $\geq$  5 mm boosted PPD reduction, CAL gain with marked radiographic linear bone refill in study group rather than in control group at 6 months post surgically.

### Financial support and sponsorship

None.

### Conflicts of interest

None.

## REFERENCES

- Atchuta, A., Gooty, J.R., Guntakandla, V.R., Palakuru, S.K., Durvasula, S., Palaparthi, R. (2020). Clinical and radiographic evaluation of platelet-rich fibrin as an adjunct to bone grafting demineralized freeze-dried bone allograft in intrabony defects. *J Indian Soc Periodontol*, 24(1), 60-66.
- Bajaj, P., Pradeep, A.R., Agarwal, E., Rao, N.S., Naik, S.B., Priyanka, N., Kalra, N. (2013). Comparative evaluation of autologous platelet-rich fibrin and platelet-rich plasma in the treatment of mandibular degree II furcation defects: a randomized controlled clinical trial. *J Periodont Res*, 48 (5), 541-676.
- Choukroun, J., & Ghanaati, S. (2018). Reductions of relative centrifugation force within injectable platelet-rich-fibrin (PRF) concentrates advances patients own inflammatory cells, platelets and growth factors: the first introduction to the low speed centrifugation concept. *Eur J Trauma Emerg Surg*, 44, 87-95.
- Fernandes, G., Abhyankar, V., M O'Dell, J. (2021). Calcium Sulfate as a Scaffold for Bone Tissue Engineering: A Descriptive Review. *J Dent Oral Disord Ther*, 9(1): 1-22.
- Galav, S., Chandrashekar, K.T., Mishra, R., Tripathi, V., Agarwal R., Galav, A. (2016). Comparative evaluation of platelet-rich fibrin and autogenous bone graft for the treatment of infrabony defects in chronic periodontitis: Clinical, radiological, and surgical reentry. *Indian J Dent Res*, 27(5), 502-507.
- Gao, P., Zhang, H., Liu, Y., Fan, B., Li, X., Xiao, X., Lan, P., Li, M., Geng, L., Liu, D., Yuan, Y., Lian, Q., Lu, J., Guo, Z., & Wang, Z. (2016). Beta-tricalcium phosphate granules improve osteogenesis in vitro and establish innovative osteo-regenerators for bone tissue engineering in vivo. *Sci Rep*, 6, 23367.
- Giannobile, W.V. (1996). Periodontal tissue engineering by growth factors. *Bone*, 19(1 Suppl): 23S-37S.
- Lei, L., Yu, Y., Ke, T., Sun, W., Chen, L. (2019). The application of three-dimensional printing model and platelet-rich fibrin (PRF) technology in guided tissue regeneration surgery for severe bone defects. *J Oral Implantol*, 45(1), 35-43.
- Leventis, M., Tsetsenkou, E., Kalyvas, D. (2020). Treatment of Osseous Defects after Mandibular Third Molar Removal with a Resorbable Alloplastic Grafting Material: A Case Series with 1- to 2-Year Follow-Up. *Materials*, 13(20), 4688.
- Liu, Y., Sun, X., Yu, J., Wang, J., Zhai, P., Chen, S., Liu, M., Zhou, Y. (2019). Platelet-rich fibrin as a bone graft material in oral and maxillofacial bone regeneration: classification and summary for better application. *Bio Med Res Int*, 2019, 1-16.
- Miron, R.J., Fujioka-Kobayashi, M., Bishara, M., Zhang, Y., Hernandez, M., Choukroun, J. (2017) Platelet-rich fibrin and soft tissue wound healing: a systematic review. *Tissue Eng Part B Rev*, 23(1), 83-99.
- Mukherji, A., & Rath, S.K. (2016). Calcium sulfate in periodontics: A time tested versatile alloplast. *J Sci Soc*, 43(1), 18-23.

- Nagaveni, N.B., Kumari, K.N., Poornima, P., Reddy, V. (2015). Management of an endo-perio lesion in an immature tooth using autologous platelet-rich fibrin: A case report. *J Indian Soc Pedod Prev Dent*, 33: 69-73.
- Pavani, M. P., Reddy, K., Reddy, B. H., Biraggari. S.K., Babu, C., Chavan, V. (2021). Evaluation of platelet-rich fibrin and tricalcium phosphate bone graft in bone fill of intrabony defects using cone-beam computed tomography: A randomized clinical trial. *J Indian Soc Periodontol*, 25(2), 138–143.
- Rosamma Joseph, V., Raghunth, A., Sharma, N. (2012). Clinical effectiveness of autologous platelet rich fibrin in the management of infrabony periodontal defects. *Singapore Dent J*, 33(1), 5-12.
- Sadiq, S., Shetty, P., Bhandary, R., Bhat, R. (2020). Treatment of Intrabony Defect Using Platelet Rich Fibrin Combined with Bioactive Glass: A Case Report of a Maxillary Central Incisor. *Indian J Public Health Dev*, 11(05).
- Saluja, H., Dehane, V., Mahindra, U. (2011). Platelet-Rich fibrin: a second generation platelet concentrate and a new friend of oral and maxillofacial surgeons. *Annals of Maxillofacial Surgery*, 1(1), 53-57.
- Sharma, A., & Pradeep, A.R. (2011). Treatment of 3-wall intrabony defects in patients with chronic periodontitis with autologous platelet rich fibrin: A randomized controlled clinical trial. *J Periodontol*, 82: 1705-12.
- Singh, S., & Vandana, K.L. (2019). Stent as an accessory tool in periodontal measurements: An insight. *J Indian Soc Periodontol*, 23(1), 81-84.
- Sukumar, S., Drízhal, I., Bukac, J., Paulusová, V., Pilathadka, S. (2010). Surgical treatment of periodontal intrabony defects with calcium sulphate in combination with beta tricalcium phosphate: a 12-month retrospective clinical evaluation. *Acta Medica*, 53(4), 229-234.
- Sunitha, R.V., & Munirathnam, N.E. (2008). Platelet-rich fibrin: evolution of a second-generation platelet concentrate. *Indian J Dent Res*, 19(1), 42-6.
- Tonetti, M.S., Greenwell, H., Kornman, K.S. (2018). Staging and grading of periodontitis: Framework and proposal of a new classification and case definition. *J Clin Periodontol*, 45(Suppl20), S149-S161.