



CASE STUDIES

ethoss[®] *Grow
Stronger_*

Ethoss Regeneration Ltd
8 Ryefield Court, Silsden, BD20 0DL, UK
www.ethoss.dental | info@ethoss.dental

LATERAL WINDOW SINUS AUGMENTATION

Male

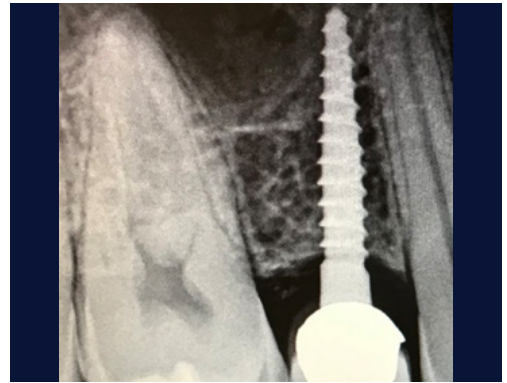
24 years old

History of chronic sinusitis following earlier implant placement

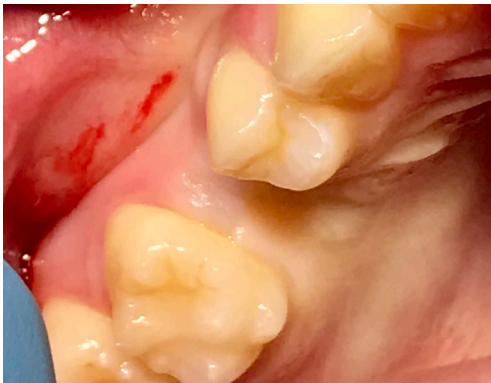MH clear, SH nil

Generally healthy dentition

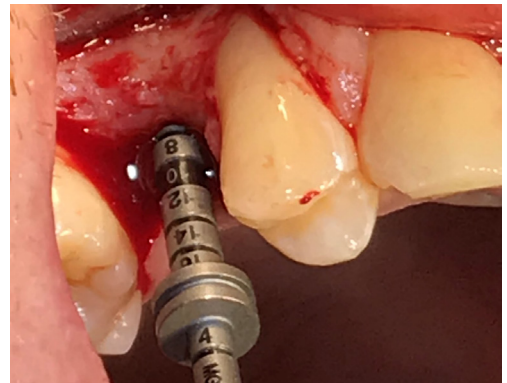Case from Dr Andrew Fish, Jersey Channel Islands



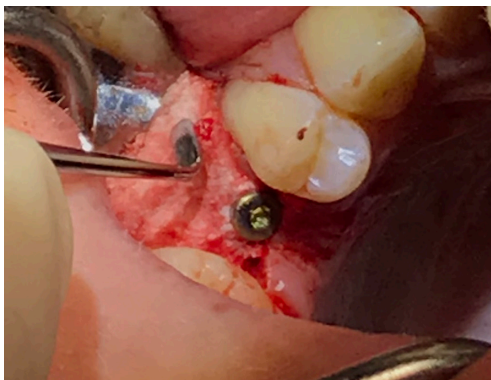
1. Initial situation - narrow one piece implant requires explantation due to infection



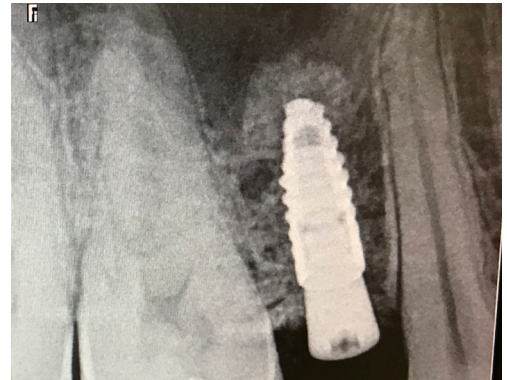
2. Implant removed and site allowed to heal, loss of buccal profile



3. Prepare osteotomy and checking depth, sinus augmentation required

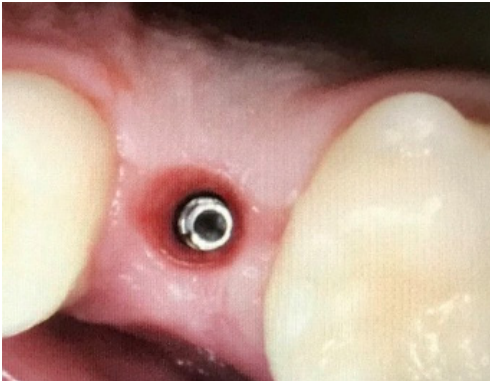


4. 3.3mm wide implant placed with simultaneous sinus graft using DASK system. Additional grafting on buccal aspect

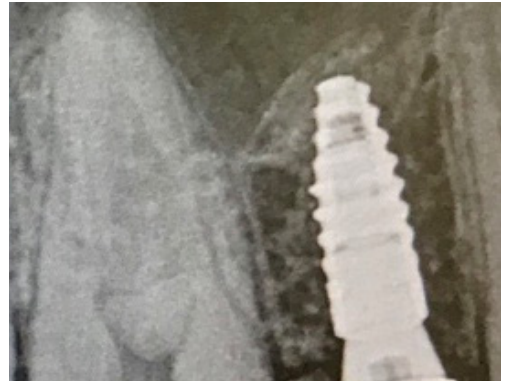

5. Graft and implant placement

LATERAL WINDOW SINUS AUGMENTATION



6. 12 weeks - ready for loading



7. Loaded 12 months



GROW STRONGER

USEFUL RESOURCES

RECOMMENDED CLINICAL PROTOCOL

Clinical study showcasing recommended clinical protocol for EthOss

Download

SURGICAL GUIDELINES

The official recommended guide on how to use EthOss

Download

HOW TO MIX ETHOSS

Explainer video

Watch