



CASE STUDIES

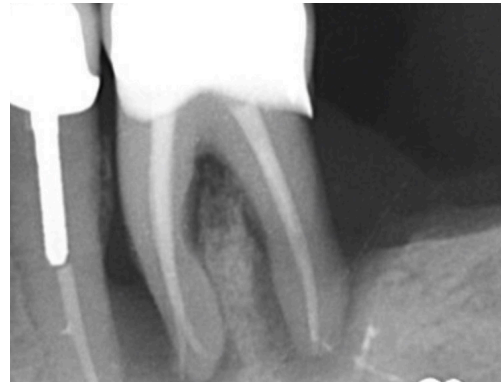ethOss[®]

Grow
Stronger[®]

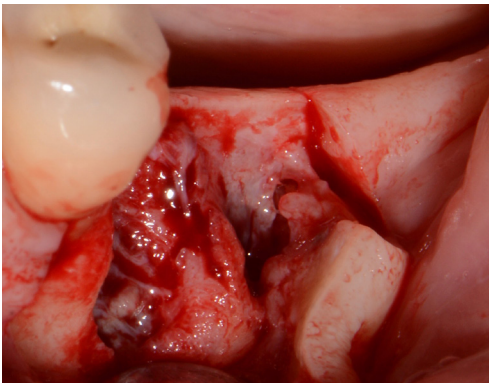
EthOss Regeneration Ltd
8 Ryefield Court, Silsden, BD20 0DL, UK
www.ethoss.dental | info@ethoss.dental

LOWER MOLAR SITE REGENERATION

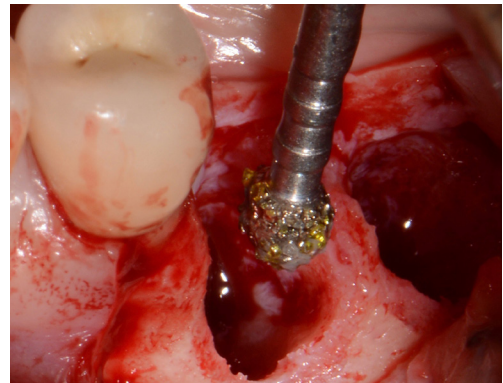
Case from Dr Peter Fairbairn



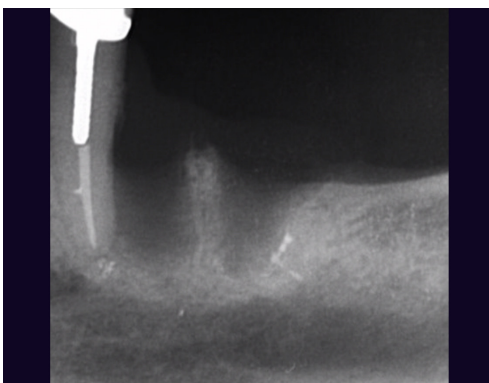
1. Initial situation



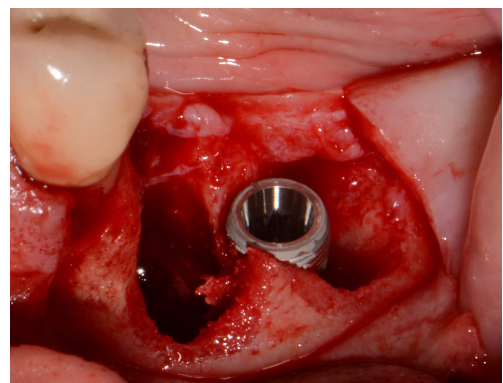
2. Flap raised 4 weeks following extraction to allow for soft tissue healing



3. Site cleaned with EthOss® Degrugation Bur, removing all soft tissue

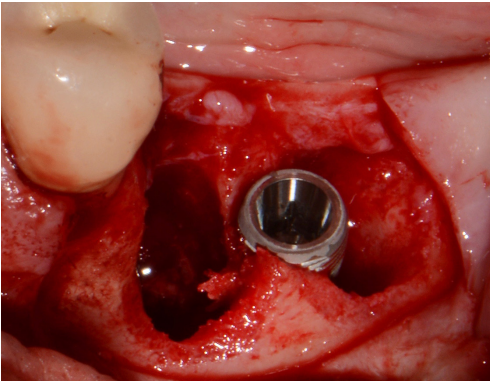


4. X-ray prior to simultaneous implant placement and grafting. Note 3-4mm to the IAN, however key factor here is angle of the mandible

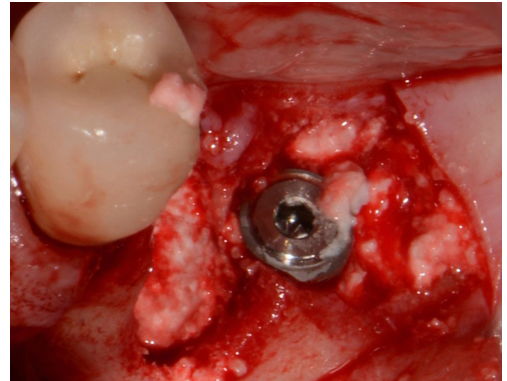


5. Implant placement – drifted slightly distal

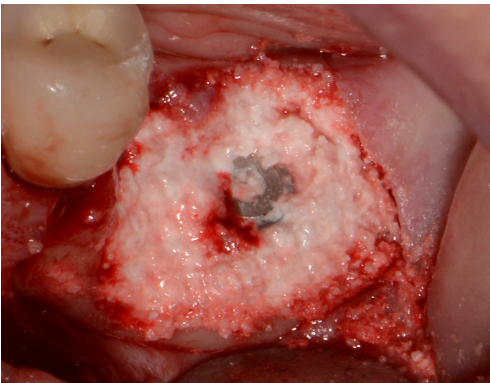
LOWER MOLAR SITE REGENERATION



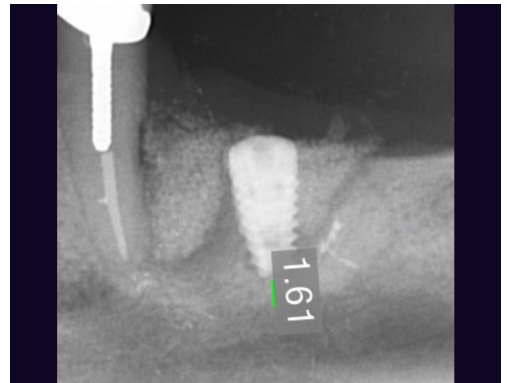
6. Implant placement



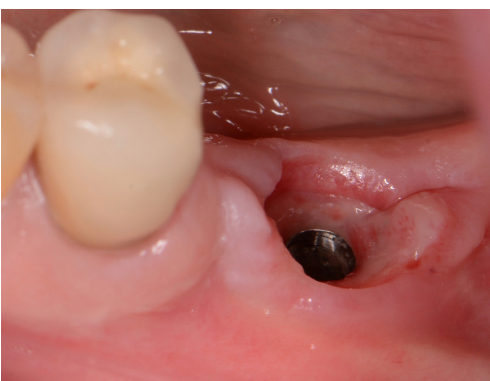7. Root socket grafted with EthOss



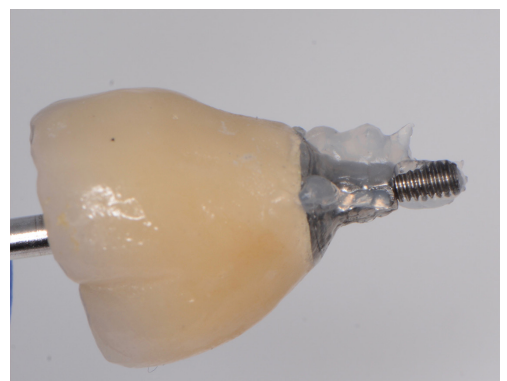8. Additional grafting. Material dried with sterile gauze for 5 minutes before flap repositioned and sutured shut



9. X-ray at placement – approx. 2.5mm to IAN and 1.5mm to angle of mandible so very low primary stability

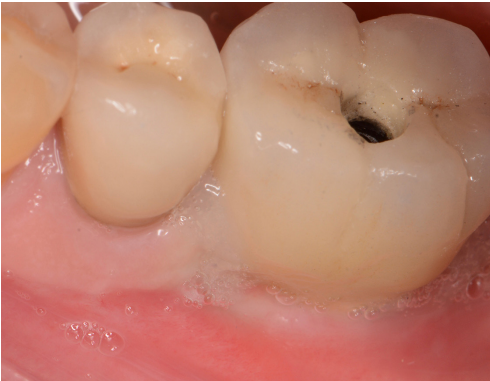

10. Uncovered at 12 weeks and healing cap fitted. Image shows 2 weeks later, patient returned for final restoration

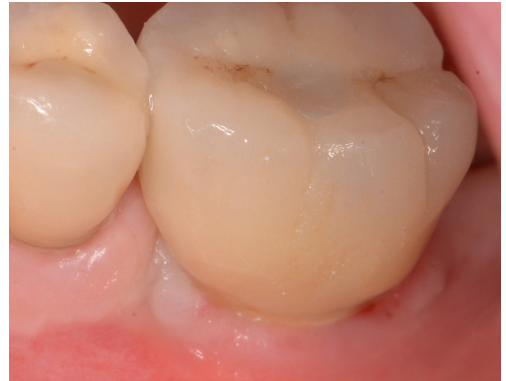

11. Final crown, screw retained

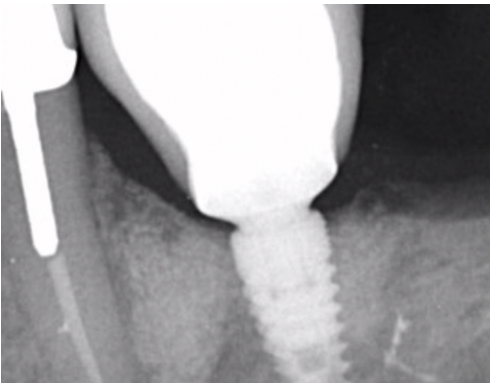
LOWER MOLAR SITE REGENERATION



12. Implant loaded, Blue@M oxygenated healing gel to improve soft tissue



13. Implant loaded



14. X-ray at 2 years, graft will have turned over to new host bone



GROW STRONGER[®]

USEFUL RESOURCES

RECOMMENDED CLINICAL PROTOCOL

Clinical study showcasing recommended clinical protocol for EthOss bone grafting material

[Download](#)

SURGICAL GUIDELINES

The official recommended guide on how to use EthOss bone grafting material

[Download](#)

HOW TO MIX ETHOSS BONE GRAFTING MATERIAL

Explainer video

[Watch](#)